

ORIGINAL ARTICLE

Correlation between projection of the ear, the inferior crus, and the antihelical body: analysis based on computed tomography

(brief title):

Ear projection and inferior crus

HIROSHI SHINOHARA¹, KIYOSHI MATSUO¹, YOSHINORI HATAYA², & KENJI TAKI³

¹Department of Plastic and Reconstructive Surgery, Shinshu University School of Medicine, Matsumoto, ²Department of Plastic Surgery, Ina Central Hospital, Ina, ³Department of Plastic Surgery, Nagano Municipal Hospital, Nagano, Japan

Correspondence: Hiroshi Shinohara, MD, Department of Plastic and Reconstructive Surgery, Shinshu University School of Medicine, 3-1-1 Asahi, Matsumoto, 390-8621, Japan. Tel: 81-263-37-2833. Fax: 81-263-37-1920. E-mail: shinop@hsp.md.shinshu-u.ac.jp

Abstract

We investigated the correlation between projection of the ear and the antihelical folding angle to clarify which portion of the antihelix should be corrected in reconstruction of prominent ears using computed tomograms of 15 ears in 11 patients with fractures of the facial bones. The angle of the scapho-triangular fossa indicating the superior crus, cymba conchae-triangular fossa angle indicating the inferior crus, and the scapho-conchal angle indicating the antihelical body were measured. There was no relation between the cranioauricular angle and the angle of the scapho-triangular fossa. However, there were significant relations between the cranioauricular angle and the cymba conchae-triangular fossa angle, and the cranioauricular and scapho-conchal angles, which suggests that emphasis should be placed on reconstruction of the inferior crus and antihelical body when prominent ears are being corrected.

Key Words: *Prominent ear, superior crus, inferior crus, antihelix body, computed tomography*

Introduction

Prominent ears are the most common congenital deformity in the head and neck region, and affecting roughly 5% of the population [1]. There are three deformities in ear structure: the valgus of the concha with a cranioauricular angle of more than 40°, underfolding of the antihelix, and hypertrophy of the concha [2]. Several techniques have been reported to correct this prominence, and emphasis has been placed on folding of the cartilage describing the antihelix [2-10]. The degree of setback depends on the shape of the antihelix, and some methods involve reconstruction of the antihelical body and superior crus [4, 7-10]. However, we know of no evidence to indicate which portion of the antihelix should be reconstructed.

Not only prominent ears but normal ears vary in their cranioauricular angle, scapho-conchal angle, cymba conchae-triangular fossa angle, and scapho-triangular fossa angle. We used computed tomography to find out whether there are any significant relations between the cranioauricular angle and scapho-conchal angle, the cranioauricular angle and the cymba conchae-triangular fossa angle, and the cranioauricular angle and the scapho-triangular fossa angle. We wished to know which portion of the antihelix should be corrected during reconstruction of prominent ears (Figure 1).

Patients and methods

Data were obtained from a retrospective review of casenotes of patients admitted to hospital with fractures of the facial bones between 2002 and 2004 at the Department of Plastic and Reconstructive Surgery, Shinshu University School of Medicine. Computed tomographic(CT) examination results of 15 ears of 11 patients were obtained, comprising slices 3mm thick in parallel with the Frankfort horizontal plane. Those with deformed ears caused by head fixation were excluded. Some with traumatic swelling of the temporal region were also excluded.

Three horizontal sections were selected for each patient. The most cephalic section was selected from some sections of the superior or inferior crus (Figure 2 lines (a) and (b)). The angle of the scapho-triangular fossa was indicated in a horizontal section obtained in the plane involving the superior crus (Figure 3a). The cymba conchae-triangular fossa angle was indicated in another horizontal section involving the inferior crus (Figure 3b). Another horizontal section was obtained in the plane involving the centre of the porus acusticus externus (Figure 2 line(c)), and the cranioauricular angle and the scapho-conchal angle were assessed (Figure 3c,d). The relations between the angles were evaluated.

For statistical analysis we used Stat-View (version 5.0, Abacus Concept, Berkeley, CA) and Pearson's correlation coefficient. Probabilities of less than 0.05 were accepted as significant.

Results

There was no significant relation between the cranioauricular angle and the scapho-conchal angle ($p=0.9$) (Figure 4a). However, another scattergram indicated a significant relation between the cranioauricular angle and the cymba conchae-triangular fossa angle ($p=0.03$) (Figure 4b). A further scattergram also showed a significant relation between the cranioauricular angle and scapho-triangular fossa angle ($p=0.03$) (Figure 4c).

Discussion

Prominent ears can be corrected in many different ways, the most important of which include formation of the antihelix and posterior bending of the cartilage. Hinderer et al.[4] suggested that one of the basic deformities in prominent ears that is present in different degrees and combinations is insufficient folding of the superior crus, and reported an operative technique to form the superior crus and antihelical body using mattress sutures. Other methods for treating prominent ears by correcting the superior crus have been reported by Thomas and

Fatah [7], Tolhurst [8], Woolf [9], and Yugueros and Friedland [10]. However, we know of no previous report that emphasize the inferior crus in correcting prominent ears.

Our CT scans of the superior or inferior crus were obtained diagonally, and so did not precisely indicate the true scapho-conchal angle or the cymba conchae-triangular fossa angle. If CT scans were taken with thinner slices more reliable data about the scapho-conchal and cymba conchae-triangular fossa angles could be obtained. However, the values measured are suitable for this comparative study, and our results are reliable.

Our 15 cases were selected at random, and may have included any patients with ear deformities. For example, shell-ear deformity is the absence or decrease of the curl of the helical rim combined with direct merging of the concha and scapha in the same plane [4]. In Stahl's ear deformity, a third transverse crus may be combined with a flat helix, lack of development of the superior crus, and deformity of the scaphoid fossa. However, external appearances and the results of our CT examinations did not indicate such complex ear deformities as those. The cranioauricular angle in our patients, indicating the prominence of the ear, varied and ranged from 23° to 89°.

Guyuron and DeLuca [11] reported a linear correlation between projection of the ear and the site of insertion of the posterior auricular muscle based on the operative measurements. This muscle consists of both oblique and transverse branches, the oblique part of which forms the inferior crus, while the transverse part forms the antihelical body. The significance of the site of insertion in the pathogenesis of prominent ears has been shown: they suggest that the prominence of the ear correlates with the inferior crus and antihelical body.

Our results do not contradict this report, and our scattergrams show that the prominence of the ear does not depend on the superior crus, but correlates with the inferior crus and the antihelical body. We suggest that the basic deformities of prominent ears are insufficient folding of the inferior rather than the superior crus. We emphasize reconstruction of the inferior crus and antihelical body for surgical correction of prominent ears (Figure 5), and the surgical results are satisfactory. Seyhan and Ozen[12] reported a case of prominent ear in which the inferior crus of the antihelical fold was absent, and concluded that construction of an inferior crus by folding a sharp edge improved the structural appearance of the auricle. Careful attention should be paid to the inferior crus and the antihelical body in cosmetic reconstruction of the ears. If the inferior crus and antihelical body are bent surgically, the auricle naturally leans toward the temporal plane.

References

- [1] Ellis DAF, Keohane JD. A simplified approach to otoplasty. *J Otoplasty* 1992; 21: 66-9.
- [2] Madzharov MM. A new method of auriculoplasty for protruding ears. *Br J Plast Surg* 1989; 42: 285-90.
- [3] Attwood AI, Evans DM. Correction of prominent ears using Mustarde's technique: an out-patient procedure under local anaesthetic in children and adults. *Br J Plast Surg* 1985; 38: 252-8.
- [4] Hinderer UT, del Rio JL, Fregenal FJ. Otoplasty for prominent ears. *Aesthetic Plast Surg* 1987; 11: 63-9.
- [5] Kaye BL. A simplified method for correcting the prominent ear. *Plast Reconstr Surg* 1973; 52: 184.
- [6] Steenfos H, Alberius P, Blomqvist G. A simple variant of surgical correction of prominent ears. *Scand J Plast Reconstr Surg Hand Surg* 1993; 27: 55-8.
- [7] Thomas SS, Fatah F. Closed anterior scoring for prominent-ear correction revisited. *Br J Plast Surg* 2001; 54: 581-7.

- [8] Tolhurst DE. The correction of prominent ears. *Br J Plast Surg* 1972; 25: 261-5.
- [9] Woolf RM. Repositioning of prominent ears. *Ann Plast Surg* 1978; 1: 155-60.
- [10] Yugueros P, Friedland JA. Otoplasty: the experience of 100 consecutive patients. *Plast Reconstr Surg* 2001; 108: 1045-53.
- [11] Guyuron B, DeLuca L. Ear projection and the posterior auricular muscle insertion. *Plast Reconstr Surg* 1997; 100: 457-60.
- [12] Seyhan A, Ozden S. An unusual antihelical deformity causing prominent ear: isolated absence of the inferior crus. *Plast Reconstr Surg* 2005; 115: 336-7.

Figure Legends

- Figure 1. (a) Lateral aspect of the prominent ear. (b) The superior crus and antihelical body are folded with the fingers to correct the prominent ear. The inferior crus is not folded. (c) For correction of the prominent ear, the inferior crus and antihelical body are folded. The superior crus is not folded.
- Figure 2. Three horizontal sections were selected from computed tomograms. (a) The most cephalic plane involving the superior crus. (b) The most cephalic plane involving the inferior crus. (c) The plane involving the centre of the porus acusticus externus.
- Figure 3. (a) The angle of the scapho-triangular fossa on the horizontal section (a) of Figure 2. (b) The cymba conchae-triangular fossa angle on the horizontal section (b) of Figure 2. (c) The angle of the scapho-triangular fossa. (d) The cranioauricular angle on the horizontal section (c) of Figure 2.
- Figure 4. (a) A scattergram showing the relation between the cranioauricular angle and the angle of the scapho-triangular fossa($r=0.036$, $p=0.9$). (b) A scattergram of the relation between the cranioauricular angle and the cymba conchae-triangular fossa angle($r=0.563$, $p=0.03$). (c) A scattergram of the relation between the cranioauricular angle and the scapho-conchal angle($r=0.56$, $p=0.03$) ($n=15$ in each group).
- Figure 5. (a) Operative findings. Marking and tattooing of the antihelical body and the inferior crus. (b) The tail of the helical cartilage is separated from the body of the ear cartilage, and access gained to the anterior surface. The skin overlying the antihelical body and the inferior crus is separated from the underlying cartilage. (c) Horizontal mattress-style sutures are used to hold the new antihelical fold. (d) The natural looking antihelix after suture of the skin.

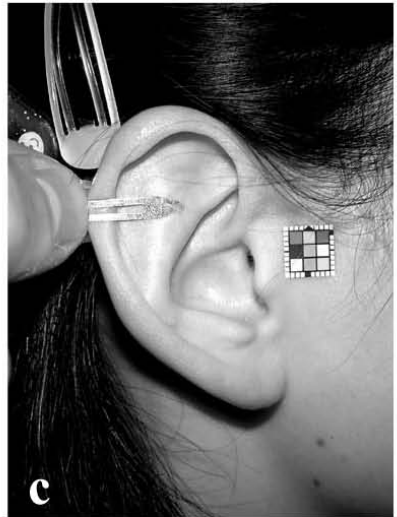
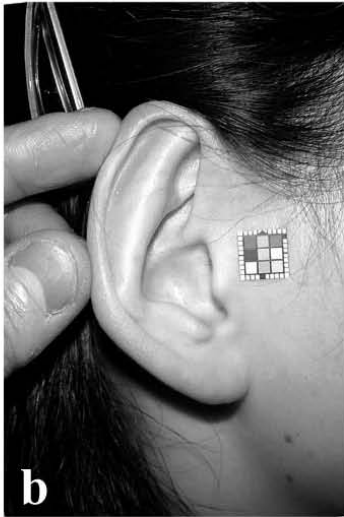
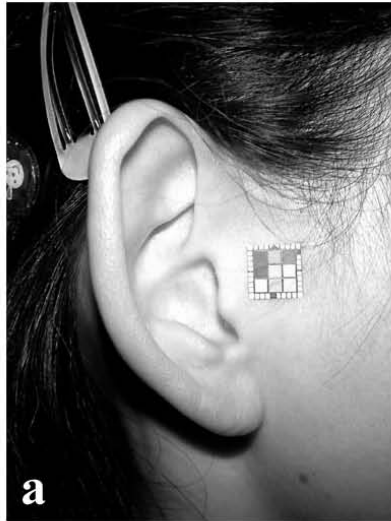Figure 1

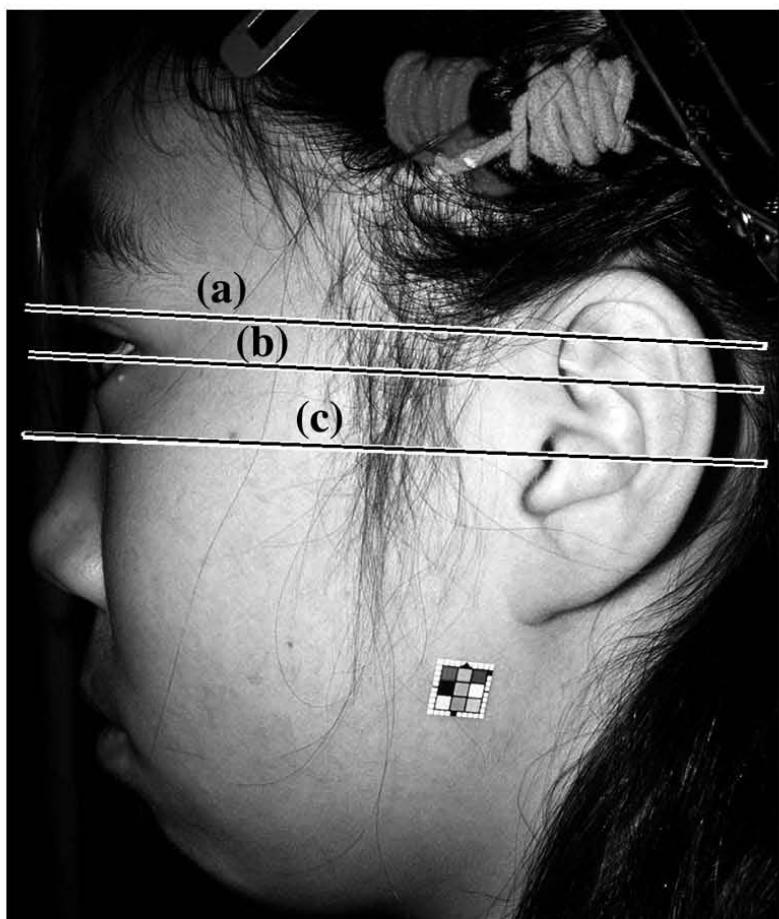


Figure 2

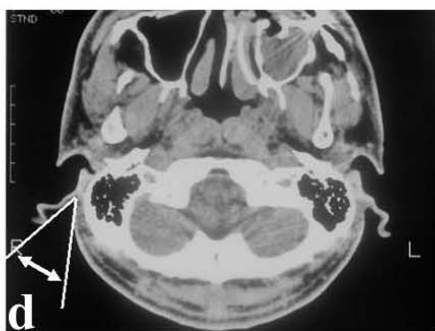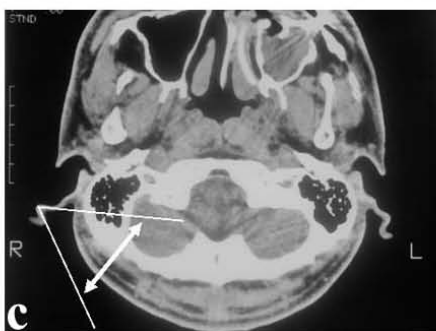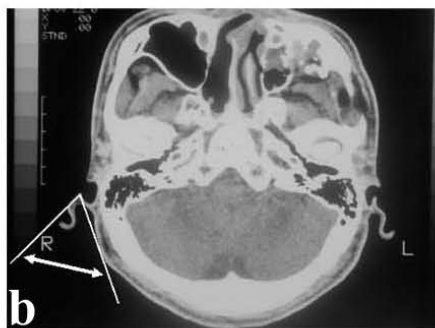


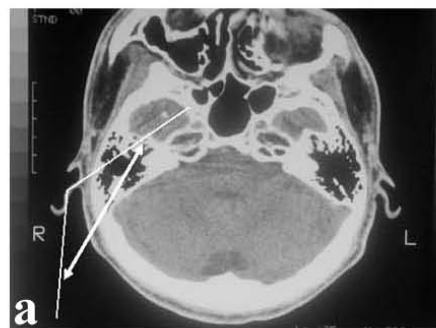Figure 3

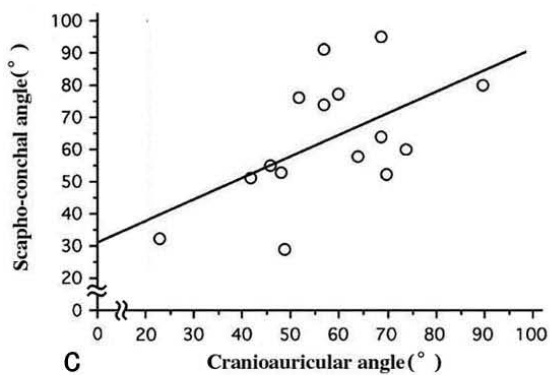
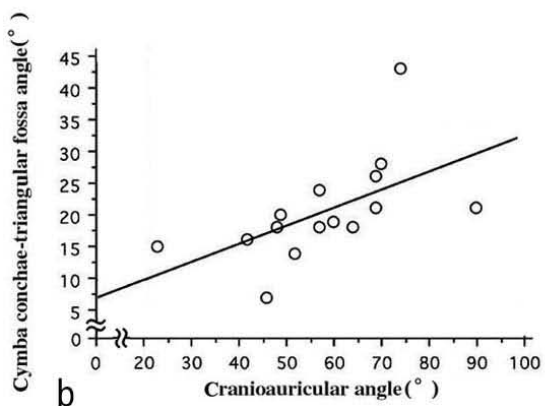
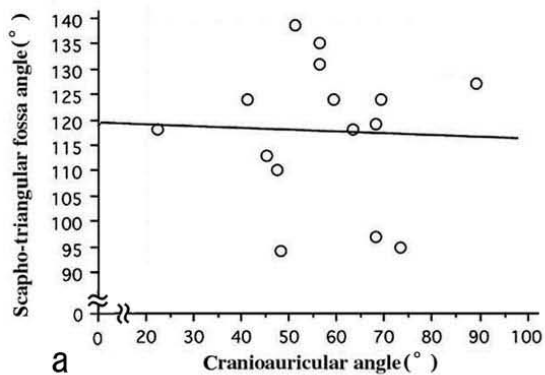


Figure 4

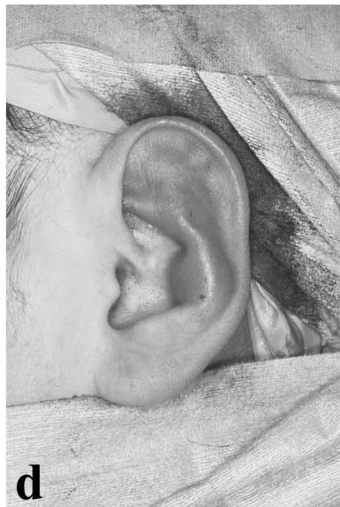
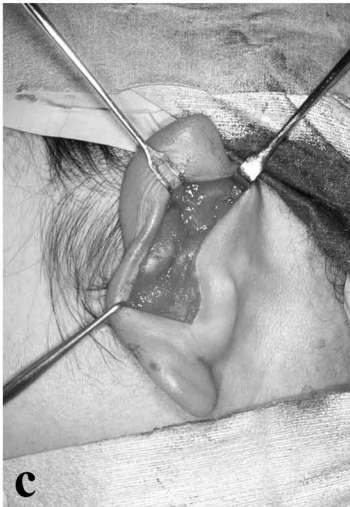
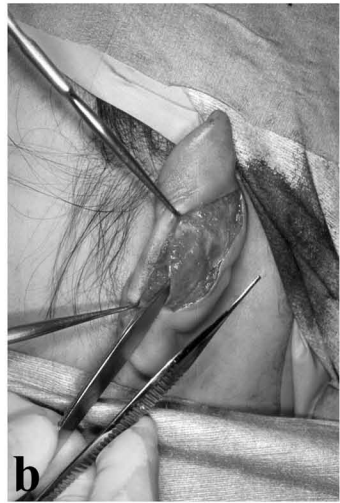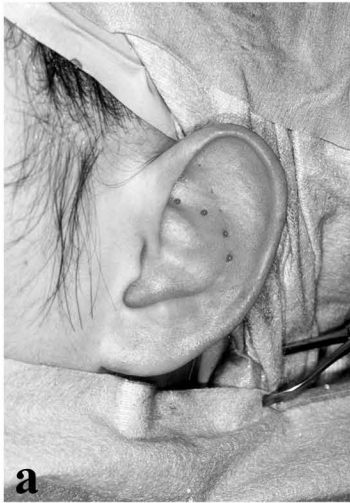Figure 5